

Skin tightening and fat reduction of double chin using Subdermal Induced Heat (S.I.H.) Technology – case report

ARNA SHAB¹, MANUELA LISANDRU¹, CATHARINA SHAB¹

KEYWORDS: Skin tightening, fat reduction, double chin, radio-frequency, long-term patient satisfaction, Subdermal Induced Heat (S.I.H.) Technology

SUMMARY:

Treatments in the field of aesthetic medicine are gaining more and more. Especially the minimally invasive therapies. The treatment of submental fat and skin laxity is becoming increasingly interesting, as it also borders the face. A range of mono- and bipolar radiofrequency devices are being used as new treatments for skin rejuvenation and tightening. We report here a case and show that subdermal induction heating technology also known as endodermal radiofrequency is one of the most effective applications of this treatment method. Possible contraindications should be considered and written down. The application of endodermal radiofrequency therapy (S.I.H. Technology) requires a comprehensive training, because to the current knowledge, the experience of the physician in the use of high-frequency devices is most important for a successful outcome.

INTRODUCTION

The desire to improve the appearance is growing steadily. Thus, the demand for non-invasive or minimally invasive treatments in aesthetic medicine is increasing rapidly. These include in particular moderate fat reduction and skin tightening. Radiofrequency therapy is one of the most effective methods for this application. There are currently several platforms based on this method. We report here a double-chin case and describe the effective method of reducing the smallest fat deposits in the submental fat associated with tightening of the skin. The effectiveness of the therapies was important to us as

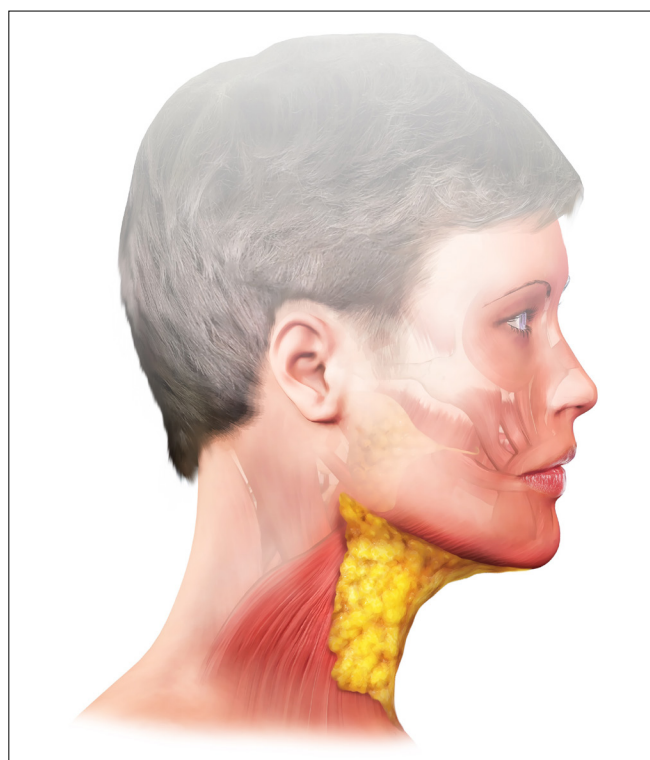


Fig. 1: Sideview on preplatysma fat.

it forms the basis for long-term patient satisfaction. This is a factor that should not be underestimated. Therefore, we report a treatment system that covers both indications fat reduction and skin tightening and is versatile, so that the user has a variable tool available [1,2].

One of the most commonly used procedures is Non-Invasive Radiofrequency (RF). This is used in particular for the treatment of skin flaccidity [3]. The temperature and depth of heating depend on the energy used and the impedance of the biological tissue [4]. The aim is to induce thermal damage to stimulate changes in the collagen composition and induce collagen neogenesis in deep layers of the skin and subcutaneous tissue [5-7].

¹ MD, Private Practice for Dermatology and Aesthetic Medicine, Frankfurt/Main, Germany

CASE

A 60-year-old female patient was treated with age-appropriate findings in the area of the chin and neck. A double chin consisting of a submental fat depot and skin flaccidity showed up. In addition, sporadically showed "age spots". She was classified as Fitzpatrick Skin Type II.

Pathological skin manifestations did not appear in the area of the area to be treated. Allergies to local anesthetics and contraindications to radiofrequency treatment, such as pregnancy, lactation, cardiac pacemakers or step maker any kind, were negative.

The patient had so far had no skin-rejuvenating treatments in this upper and lower skin area in the sense of dermal fillers, thread-lifting previously performed.

ANATOMY OF DOUBLE CHIN - SUBMENTAL FAT

What we call a double chin is a layer of submental fat on the ventral neck that creates a fold that shows the appearance of a second chin. In the submental region, the deep layers of muscle and fascia are formed above it a subcutaneous fat layer. This superficial layer of fat is shared by the platysma, a caudal continuation of the superficial muscular aponeurotic system (SMAS).

The boundaries of the compartments are formed by fascia septids emanating from the deep fascia or the periosteum and inserting themselves into the dermis. The general attractiveness and the juvenile appearance of an asthenic neck are due to this submental fatness. Bitner et al. developed a classification scheme to assess the degree of turkey-eating deformity in the submental region based on changes in the skin, fat, platysma, and underlying bone. This classification serves as an invaluable tool for evaluation and subsequent intervention [8-10].

SUBDERMAL INDUCED HEAT (S.I.H.) TECHNOLOGY – THE APPLICATION

The patient was treated with the S.I.H.T System. This is technically a monopolar, controlled heating of tissue layers of different depths with high-frequency current, voltage and frequency modulation. This application can be controlled by a thermal imaging camera via a monitor platform. It is recommended to apply before treatment a local anesthetic injection in the area of the entry point of the probe of the RF. Topical anesthesia cream, nerve block or tumescent anesthesia are not necessary in such a therapy. The insertion of the probe itself is almost painless. Only the point of entry will be painful, so local

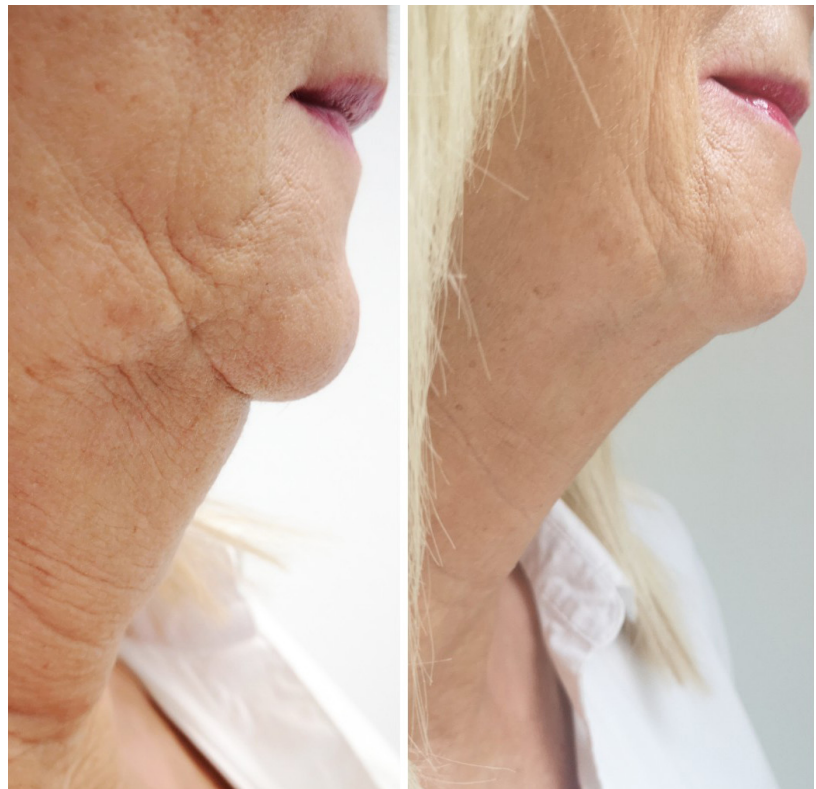

Fig. 2: Left before treatment; Right 8 weeks after treatment.

anesthesia is necessary at this entry point. The heat in the tissue leads to a uncomfortable burning sensation. This can not be prevented by larger amounts of anesthetic.

A direct reintegration into social life was possible and she returned to work. An immediateresult was not visible. The treatment was very well tolerated with only a few mild side effects. Only a burning sensation was reported as a major side effect. However, this was well tolerated by the patient. The minimal side effects such as erythema or bruising disappeared spontaneously after a few days. No major complications (eg infectious processes, necrosis, embolism, overcorrection, allergies) were observed.

DISCUSSION

When using this high frequency device, the choice of treatment depth can be treated either subdermally or subcutaneous fat tissue. The effects in these different tissues are very different. In the treated fat layers, apoptosis is induced, i.e. the medium-term breakdown of fat cells. On the other hand, the system on the dermis has an influence on the function of the cell activity as well as on the extracellular matrix in order to achieve a tightening by restructuring the collagen fibers and stimulating the fibroblasts. Here is this system unique. Unlike other devices, heat does not pass through all layers of the skin, but directly from the bottom of the dermis. In this way, no heat loss occurs at the destination (treatment point) because the probe applies the desired temperature to the target site [11,12].

The principle of RF skin tightening treatments is not new as it is known that the dermis and subcutaneous tissue will heat up and stimulate the remodeling of dermal collagen. It is well documented that heating the skin causes an immediate change in collagen structure, followed by long-term stimulation of neo-collagenesis [13]. We took advantage of these thermal effects to improve the appearance of wrinkles, the flaccidity of the skin and the contours around the face [14].

CONCLUSION

Double chin is an aesthetically very disturbing appearance. For this, subdermal induction heating technology (S.I.H.T.) is a safe, low-risk and easy-to-use treatment option. It should only be done by a doctor and offers a particularly good alternative method of skin tightening and fat reduction. Especially for the submental area it offers a very good treatment option.

Local treatment with endodermal radiofrequency (S.I.H.T.) shows high efficiency through clinical trials and analyzes. This innovative treatment is characterized by high compatibility. Thus, a realistic satisfaction of the patient expectation can be achieved with an excellent visible effect.

Address of Correspondence:

Arna Shab, MD
Hanauer Landstrasse 151 – 153,
DE-60314 Frankfurt am Main
arna.shab@med-aesthet.de

References

1. McCollough EG, Perkins S, Thomas JR (2012) Facelift: Panel Discussion, Controversies, and Techniques. *Facial Plast Surg Clin North A* 20: 279-325.
2. Lee HS, Lee DH, Won CH, Chang HW, Kwon HH, Kim KH, et al. (2011) Fractional Rejuvenation Using a Novel Bipolar Radiofrequency System in Asian Skin. *Dermatol Surg* 37: 1611-9.
3. Brightman L, Goldman MP, Taub AF (2009) Sublative Rejuvenation: Experience With a New Fractional Radiofrequency System for Skin Rejuvenation and Repair. *J Drugs Dermatol* 8: s9-13.
4. Belenky I, Margulis A, Elman M, Bar-Yosef U, Paun SD (2012) Exploring Channeling Optimized Radiofrequency Energy: a Review of Radiofrequency History and Applications in Esthetic Fields. *Adv Ther* 29: 249-66.
5. Alster T S, Jason R L (2007) Nonablative cutaneous remodeling using radiofrequency devices. *Clin Dermatol* 25: 487-91.
6. Harth Y, Lischinsky D (2011) A novel method for real-time skin impedance measurement during radiofrequency skin tightening treatments. *J Cosmet Dermatol* 10: 24- 9.
7. Adatto M. A., Adatto-Neilson R. M., Morren G (2014) Reduction in adipose tissue Volume using a new highpower radiofrequency technology combined with infraredlight and mechanical manipulation for body contouring. *Lasers Med S* 29: 1627 – 1631.
8. Chow S1, Bennett RG (2015) Superficial Head and Neck Anatomy for Dermatologic Surgery: Critical Concepts. *Dermatol Surg* 41 Suppl 10: S169-77.
9. Vistnes L M, Souther S G (1983) The platysma muscle. Anatomic considerations for aesthetic surgery of the anterior neck. *Clin Plast Surg* 10: 441-448.
10. Ellenbogen R, Karlin JV (1980) Visual criteria for success in restoring the youthful neck. *Plast Reconstr Surg* 66: 826-837.
11. Helbig D, Moebius A, Simon JC, Paasch U (2010) Nonablative skin rejuvenation devices and the role of heat shock protein 70: results of a human skin explant model. *J Biomed Opt* 15: 038002.
12. Sadick NS, and Makino Y (2004) Selective electro-thermolysis in aesthetic medicine: a review. *Lasers Surg Med* 34: 91-97.
13. Sadick NS, Sato M, Palmisano D, Frank I, Cohen H, Harth Y (2011) In vivo animal histology and clinical evaluation of multisource fractional radiofrequency skin resurfacing (FSR) applicator. *Journal of Cosmetic and Laser Therapy* 13: 204-209
14. Treatment of Skin Laxity Using Multisource, Phase- Controlled Radiofrequency Yohei Tanaka Additional information is available at the end of the chapter <http://dx.doi.org/10.5772/intechopen.71749>.